Pathology in Practice

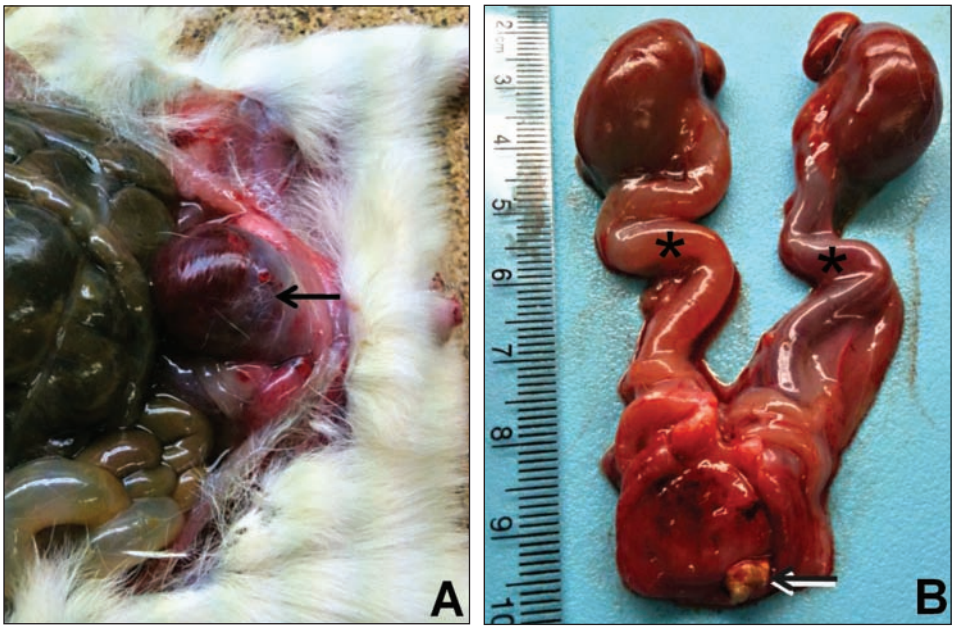

Figure 1—Photographs of the abdominal cavity (A) and the excised urinary tract (B) of a young adult male Hartley guinea pig (*Cavia porcellus*) that died suddenly. Although the guinea pig had been removed from an active research study because of poor weight gain and growth, no other clinical signs were evident prior to death. A—The urinary bladder (arrow) is markedly distended and hemorrhagic and occupies most of the caudal portion of the abdominal cavity. B—Both ureters (asterisks) are severely dilated, and both kidneys are slightly enlarged and flaccid. The urinary bladder has been cut open; notice the 4-mm-diameter urolith (calculus) on the hemorrhagic and thickened urinary bladder mucosa (arrow).

History

A young adult male Hartley guinea pig (*Cavia porcellus*) weighing 197 g (0.43 lb) was evaluated at the Comparative Pathology Branch, US Army Medical Research Institute of Chemical Defense, Aberdeen Proving Ground, Edgewood, Md, for a complete necropsy following sudden death; it had been observed alive approximately 1 hour earlier. The guinea pig, originally assigned to an active neurobehavior research protocol, was not used for that study because of low weight and poor growth.

This report was submitted by Derron A. Alves, DVM, DACVP; from the Comparative Pathology Branch, US Army Medical Research Institute of Chemical Defense, 3100 Ricketts Point Rd, Aberdeen Proving Ground, Edgewood, MD 21010.

The views, opinions, and findings contained herein are those of the author and should not be construed as an official Department of Army position, policy, or decision unless so designated by other documentation.

The author thanks Krista Bruno Williamson, Erin Sarricks, John Hengemihle, Denise Kniffin, Cathy Holmes, and Erin O'Keefe for technical assistance and Tracey Hamilton for digital imaging and figure preparation.

The US Army Medical Research Institute of Chemical Defense is fully accredited by the Association for Assessment and Accreditation of Laboratory Animal Care International. Although the animal described in this report was not assigned to an active research protocol, research at the US Army Medical Research Institute of Chemical Defense is conducted in compliance with the Animal Welfare Act and other federal statutes and regulations relating to animals and experiments involving animals and adheres to principles stated in the Guide for the Care and Use of Laboratory Animals, National Research Council, 2011.

Address correspondence to Dr. Alves (derron.a.alves@us.army.mil).

Clinical and Gross Findings

The carcass was received in good condition with minimal amounts of subcutaneous and visceral adipose tissue. Fresh, unclotted blood was present within the penile sheath and urethral orifice and stained the perineum; the other most noteworthy lesions observed during the gross postmortem examination were localized to the urinary system (**Figure 1**). Both kidneys were mildly enlarged with diffuse reddish-tan cortical discoloration and appeared soft and flaccid. The renal pelvises were mildly dilated with blood-tinged urine and contained variable amounts of yellowish-tan grainy material; the right kidney was more severely affected. Bilaterally, the ureters were severely distended with similar blood-tinged urine (the diameter of each ureter was at least 5 times the diameter expected of an apparently normal ureter). The urinary bladder had a thickened, firm wall with noticeable compression of the distal ureteral openings at the trigone and was severely distended with dark-red urine admixed with yellowish-tan grainy material. A 4-mm-diameter, yellowish-tan, firm calculus was also present in the urinary bladder lumen. Calculi were not observed in the renal pelvises, penile urethra, or ureters.

Formulate differential diagnoses from the history, clinical findings, and Figure 1—then turn the page →

Histopathologic and Microbiological Findings

Of the various tissue samples processed for histologic examination, those of most interest were associated with the urinary and reproductive tracts. Histologic examination of sections of the urinary bladder revealed multiple areas of mucosal erosion and ulceration with hemorrhage, congestion, and a subepithelial inflammatory infiltrate composed mostly of heterophils, macrophages, and lymphocytes admixed with cellular and necrotic debris and granulation tissue (evidence of chronic-active inflammation; **Figure 2**). In the most severely affected areas, there was sloughing and loss of the overlying mucosal epithelium. A cross-sectional sample through the midportion of the urethra and vasa deferentia was also submitted for examination. The mucosal epithelium of the vasa deferentia was severely ulcerated and replaced by numerous degenerate heterophils admixed with necrosis, hemorrhage, and fibrin that extended into the subepithelial connective tissue and surrounding muscle layers (ulcerative and necrotizing deferentitis [or vasitis]). Although comparatively less affected, the mucosal epithelium of the urethra was eroded with occasional sloughing. The adjacent vasa deferentia and urethral serosal connective tissue were edematous, hemorrhagic, and fibrinous and infiltrated by inflammatory cells. Notable histopathologic lesions were not observed in the submitted sections of testes (with epididymis) or the accessory sex glands.

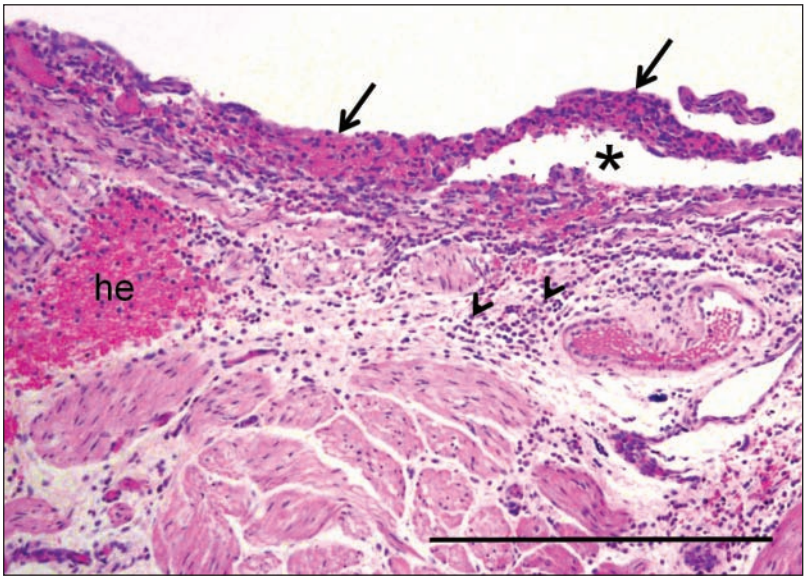

Figure 2—Photomicrograph of a section of urinary bladder from the guinea pig in Figure 1. Erosion and ulceration of the mucosal epithelium (arrows) are extensive; replacement of the mucosal epithelium with hemorrhage and necrotic cellular debris is common. Notice the separation of the mucosa from the underlying lamina propria and subepithelium (asterisk). The lamina propria is infiltrated and expanded by numerous inflammatory cells (arrowheads) admixed with hemorrhage (he), fibrin, and edema that extend into the urinary bladder musculature. H&E stain; bar = 500 µm.

Within as much as 50% of the renal cortices of both kidneys, the proximal convoluted tubules, collecting tubules, and Bowman spaces were mildly to moderately dilated and occasionally contained eosinophilic proteinaceous fluid. The severely affected tubules were lined primarily by enlarged epithelial cells with swollen, microvacuolated cytoplasm, consistent with tubular epithelial degeneration (**Figure 3**). Histologic evidence of tubular necrosis (eg, nuclear pyknosis, karyorrhexis, or karyolysis; intratubular cellular debris; and hyalinized or granular casts) was rarely seen. Likewise, despite the prominent gross postmortem lesions, histopathologic changes indicative of progressive obstructive uropathy, such as low numbers of glomeruli, glomerular hyalinization, and cortical cysts, were not observed in the kidneys of the guinea pig of this report. Multifocally surrounding and separating tubules, there was minimal interstitial fibrosis and lymphocytic and plasmacytic inflammation, considered to be an incidental background lesion and not directly attributed to the underlying disease condition. A urine sample, collected from the urinary bladder during the postmortem examination, underwent microbial culture; the results were negative for infectious organisms. The histopathologic changes associated with the ureters were minor in comparison to the severe bilateral dilation observed grossly. Although there was multifocal attenuation, erosion,

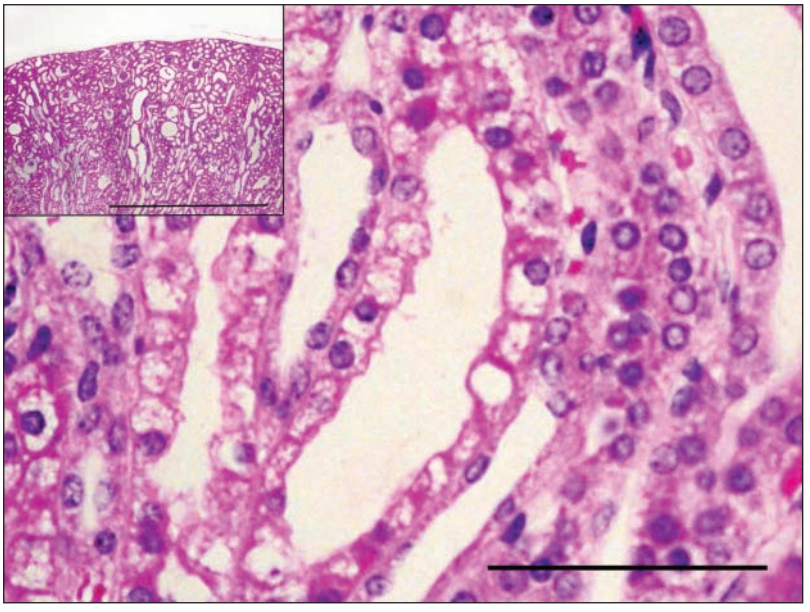

Figure 3—Photomicrographs of a section of the right kidney from the guinea pig in Figure 1. Several dilated proximal convoluted tubules in the renal cortex are lined by swollen epithelial cells with microvacuolated cytoplasm, consistent with renal tubular degeneration. H&E stain; bar = 100 µm. Inset—Throughout the renal cortex, there is extensive dilation of the renal tubules and Bowman spaces. H&E stain; bar = 2 mm.

and occasional loss of the ureteral mucosal epithelium, the most noteworthy changes were those in the adjacent serosa, including the presence of edema, hemorrhage, and infiltrating heterophils.

Morphologic Diagnosis

Marked, multifocal, necrotizing, hemorrhagic, and ulcerative cystitis; severe diffuse, bilateral, ulcerative, and necrotizing deferentitis (or vasitis) with serosal hemorrhage, fibrin, and edema; moderate to marked, bilateral, multifocal, tubular dilatation of the kidneys, with tubular degeneration; and mild to marked, bilateral, multifocal attenuation, erosion, and loss of the mucosal epithelium of the ureter and urethra, with serosal edema and hemorrhage.

Comments

For the guinea pig of this report, urolithiasis with secondary hemorrhagic cystitis, hydroureter, and obstructive nephropathy was the likely cause of the poor weight gain and growth. In general, obstructive urolithiasis in guinea pigs and other species has similar clinical, gross, and histopathologic features. Urolithiasis in guinea pigs, particularly in the urinary bladder and penile urethra of older males, has been described, although results of other studies[1,3–5,7,8] suggest that older female guinea pigs are overrepresented. Nonetheless, under certain predisposing conditions such as decreased or low water intake, small calculi (which can be found in the urine of healthy guinea pigs) may accumulate and form larger stones. Larger stones may accumulate in the penile urethra and urinary bladder, causing partial obstruction of the urinary flow and subsequent hydronephrosis and hydroureter; they may also become a constant source of mechanical irritation and trauma to the urinary tract, enhancing bacterial multiplication and resulting in a severe urinary tract infection.[4,6,7]

Guinea pig urine is typically alkaline and may contain phosphate and carbonate crystals. In 1 study,[3] microscopic examination of urine sediment samples from 21 guinea pigs with urolithiasis revealed calcium carbonate (most common; 7 [33%] guinea pigs), magnesium ammonium phosphate, amorphous phosphate, and calcium oxalate crystalluria. However, despite the variety of crystals detected during sediment examination, polarized light microscopy, infrared spectroscopy, and x-ray diffractometry revealed that the majority (> 88%) of uroliths were composed solely of calcium carbonate.[3] This finding suggests that crystals detected during urine sediment examination may not be predictive of the mineral composition of urinary calculi in guinea pigs.[3] Although urine sediment examination and mineral composition assessment were not performed for the guinea pig of this report, the composition of the urinary bladder calculus was considered most likely calcium carbonate.

Escherichia coli, *Streptococcus pyogenes*, *Staphylococcus* spp, and *Corynebacterium renale* have been isolated from the urinary tracts of laboratory guinea pigs with urinary calculi.[3,4] However, microbial culture of a urine sample collected from the guinea pig of this report during postmortem examination yielded no growth of infectious organisms. Additionally, infectious organisms were not evident in sections of the kidneys or urinary bladder during routine histologic examination or examination following application of special histochemical stains (Brown-Brenn and Brown-Hopps [for gram-positive and gram-negative organisms], Gomori methenamine silver, and periodic acid–Schiff stains) specific for bacteria and fungi. These findings suggest that the cause of the hemorrhagic cystitis detected during postmortem examination of the guinea pig of this report may be unrelated to microbial infection. It has been suggested that the incidence of cystitis in guinea pigs may increase as the animals age.[4] In a more recent study,[3] medical records for 52 guinea pigs with urolithiasis were reviewed; the median age for the 46 guinea pigs for which age had been recorded was 3 years (range, 0.5 to 5 years). The age of the guinea pig of the present report was not known. In the absence of information regarding the animal's age and detectable urinary tract infection, the likely cause of the hemorrhagic and ulcerative cystitis appeared to be urinary bladder mucosal trauma and irritation.

Complete absence of clinical signs is not unusual in guinea pigs with mild urolithiasis. Dysuria or anuria, hunched posture and vocalization during voiding, hematuria, anorexia, and listlessness are evident in more severely affected animals.[6] When present inside the prepuce, calculi may be palpable and removed manually by extruding the penis. However, radiography is likely the best option for antemortem detection, particularly when the calculi are located in the urethra or urinary bladder.

In addition to low water intake and bacterial infection, a nutritional imbalance should also be considered as a possible cause of urolithiasis in guinea pigs. Calculus formation is more likely to occur in guinea pigs that are fed diets with high calcium or vitamin D content. Acidification of the urine by feeding foods with a high acid content or supplementing the diet with vitamin C may dissolve small calculi or reduce stone formation, respectively.[6] When conservative management is unsuccessful, cystotomy with removal of the calculi and subsequent antimicrobial treatment has been reported to be successful.[2,6]

References

1. Fehr M, Rappold S. Urine matter formation in 20 guinea pigs (*Cavia porcellus*). *Vet Pract* 1997;5:553–557.
2. Harkness JE, Wagner JE. Clinical procedures. In: *The biology and medicine of rabbits and rodents*. 4th ed. Media, Pa: Williams & Wilkins, 1995;125.
3. Hawkins MG, Ruby AL, Drazenovich TL, et al. Composition and characteristics of urinary calculi from guinea pigs. *J Am Vet Med Assoc* 2009;234:214–220.
4. Peng X, Griffiths JW, Lang CM. Cystitis, urolithiasis and cystic calculi in ageing guinea pigs. *Lab Anim* 1990;24:159–163.
5. Quesenberry KE. Guinea pigs. *Vet Clin North Am Small Anim Pract* 1994;24:67–88.
6. Richardson VCG. The urinary system. In: Sutton JB, Swift ST, eds. *Diseases of the domestic guinea pig*. 2nd ed. Oxford, England: Blackwell Science Ltd, 2000;39–44.
7. Spink RR. Urolithiasis in a guinea pig. *Vet Med Small Anim Pract* 1978;73:501–502.
8. Stuppy DE, Douglass PR, Douglass PJ. Urolithiasis and cystotomy in a guinea pig. *Vet Med Small Anim Clin* 1979;74:565–567.
9. Wood M. Cystitis in female guinea pigs. *Lab Anim Sci* 1981;15: 141–143.